

*Full Length Research Paper*

# Healing and topical anti-inflammatory activities of the total aqueous bark extract of *Combretum glutinosum* Perr. (Combretaceae)

Madièye Sène<sup>1</sup>, Firmin Sylva Barboza<sup>1</sup>, Abdou Sarr<sup>2</sup>, Alioune Dior Fall<sup>2</sup>, Yacine Ndione<sup>1</sup> and Guata Yoro S. Y.<sup>1\*</sup>

<sup>1</sup>Laboratoire de Pharmacologie et Pharmacodynamie, Faculté de Médecine, de Pharmacie, et d'Odontologie (FMPO), Université Cheikh Anta Diop (UCAD), BP 5005, Dakar (Sénégal)

<sup>2</sup>Laboratoire de Pharmacognosie, Faculté de Médecine, de Pharmacie, et d'Odontologie (FMPO), Université Cheikh Anta Diop (UCAD), BP 5005, Dakar (Sénégal)

Received 18 November, 2019 ; Accepted 14 February, 2020

***Combretum glutinosum* Perrot. Ex DCs (Combretaceae) is a plant used in Senegalese traditional medicine. Its trunk barks are used to treat burns and wounds. The objective of this study was to evaluate the healing effect and topical antiinflammatory activity of the aqueous bark extract of *C. glutinosum* in second degree burn and croton oil induced ear edema in mice. Phytochemically, the aqueous bark extract of *C. glutinosum* contains tannins and flavonoids, but not alkaloids. Experimental second degree burn was induced in dorsal flanks of the rats. Topical antinflammatory activity was performed in ear edema of mice induced with croton oil. The daily application of aqueous bark extract ointment of *C. glutinosum* 3 and 10% in petroleum jelly (CGPJ-3%, CGPJ-10%) induced concentration-dependent healing effect with complete tissue repair. In fact, the daily application of CGPJ-3% was associated with total cicatrization after 28 days of treatment (score 0). CGPJ-10% induced a shift in the healing curve to the left with almost complete tissue repair in 20 days (score 1). CGPJ-10% significantly prevented ear edema in mice. The percentage increase in ear edema was  $42.78 \pm 4.94$  vs  $70.59 \pm 18$  in control group ( $p < 0.05$ ). *C. glutinosum* trunk bark induced cicatrization, probably involving tannins and flavonoids, which justifies its use in traditional medicine to treat burns and wounds.**

**Key words:** *Combretum glutinosum*, barks, burn, inflammation

## INTRODUCTION

Healing is a complex process, involving a series of biochemical and cellular reactions that promote inflammatory process, repair and remodeling of damaged

tissues (Sadaf et al., 2006). These reactions are triggered in response to an injury and restore the function and integrity of damaged tissues (Kumar et al., 2007).

\*Corresponding author. E-mail: [guata.sy@gmail.com](mailto:guata.sy@gmail.com) Tel: 00221 77 230 11 99.

Author(s) agree that this article remain permanently open access under the terms of the [Creative Commons Attribution License 4.0 International License](https://creativecommons.org/licenses/by/4.0/)

**Table 1.** Phytochemical characterization.

Phytochemical constituents	Migration solvent	Control	Revelation reagent
Tannins	Ethyl acetate/Methanol/Water (40:8:5)	Gallic acid	Ferric chloride 2%
Flavonoids	15% acetic acid in water	Quercetin	Aluminum chloride 5% in a mixture Water/ Methanol (1:1)
Alcaloids	Chloroform/Diethylamine (45:5)	Cinchonin	Dragendorff Reagent

Inflammatory response is regarded as the first among many mechanisms involved in the healing process (Eming et al., 2007). However, when it is maintained, especially in chronic wounds, such as diabetic wounds, it becomes harmful (Rosique et al., 2015). The introduction of anti-inflammatory agents or healing products with anti-inflammatory activity in wound management could be a beneficial strategy to improve wound healing (Dissemond et al., 2002).

In traditional medicine, plants are widely used to facilitate wound healing with a high degree of therapeutic success (Muthu et al., 2006; Mesfin et al., 2009; Esimone et al., 2008). This is the case of the bark of *Combretum glutinosum* (Combretaceae) Perrot. Ex DCs which is used as a poultice to treat injuries and other wounds (Sereme et al., 2011).

In Senegal, *C. glutinosum* is the most widespread species of the genus *Combretum* (Kerharo and Adam, 1974). It is called "Ratte" in Wolof (Senegal). It belongs to an essentially tropical family, the Combretaceae. It is found in savannahs and forests, on sandy or clay soils and on lateritic soils as a shrub or small tree. It is also widespread in many African countries: Gambia, Mali, Guinea, Sierra Leone, Ivory Coast, Ghana, Benin, Nigeria, Niger, Cameroon, Central African Republic and Sudan (Dione, 1996).

Phytochemically, the trunk bark of *C. glutinosum* contains tannins, flavonoids and triterpenes (Sereme et al., 2011; Yahaya et al., 2012). Several studies have reported anti-infective, antioxidant, hypoglycemic, cytotoxic, hepatoprotective and anti-inflammatory properties of extracts and molecules of *C. glutinosum* (Baba-Moussa et al., 1999; Kaboré et al., 2003; Ouattara et al., 2006; Baldé et al., 2016; Sall et al., 2017).

The purpose of this study is to evaluate the topical healing and anti-inflammatory activity of *C. glutinosum* trunk bark on experimental burn model in rats and inflammatory croton oil edema in mice.

## MATERIALS AND METHODS

### Plant material

The plant material is made of *C. glutinosum* bark harvested in the eastern region of Senegal (Tambacounda). The plant was identified at the Pharmacognosy and Botany Laboratory of the Faculty of Medicine, Pharmacy and Odontology, Cheikh Anta DIOP University (CADU), Dakar; where the voucher specimen (DPB-16-10) was

deposited.

The barks were cut and dried at 25°C for 3 weeks. A brown powder was obtained after spraying.

### Animal material

Wistar Kyoto strain rats weighing between 100 and 400 g and albino mice were used. The rats were obtained from the Pharmacology Laboratory, Faculty of Medicine, Pharmacy and Odontology, CADU. Meanwhile, the mice were obtained from the Pasteur Institute, Dakar and weighed between 27 and 38 g. The animals were housed in a cage under conditions of 25±2°C temperature, 12 h light cycle and provided with food and water *ad libitum*.

### Experimental procedure

#### Extraction

*C. glutinosum* bark powder (225 g) was decocted in 3 L of boiling water for 30 m. After cooling, the decoction was filtered (filtrate 1) and the marc was placed in 2 L of water twice and the mixture was filtered (filtrate 2 and 3).

The combined filtrates were then concentrated using a rotary evaporator and then dried at a temperature of 40°C. The weight of the total dried aqueous extract of *C. glutinosum* was 29.38 g (13.06% (w/w)) dry bark powder. The total aqueous extract obtained was used to prepare the ointments for pharmacological tests (Chang et al., 2012; Mayba and Gooderham, 2017).

#### Phytochemical characterizations

Phytochemical characterization of flavonoids, tannins, alkaloids and sterols/triterpenes was performed on tubes and confirmed by thin layer chromatography (TLC).

Aluminum chloride was used to determine flavonoids, ferric chloride for evidence of tannins, Dragendorff's reagent for alkaloids identification and acetic anhydride combined with chloroform and sulfuric acid for sterols/ triterpenes characterization (Bassène, 2012) (Table 1).

#### Ointments formulation

From the powdered *C. glutinosum* bark aqueous extract, two ointments (CGPJ-3%, CGPJ-10%) were prepared.

Sodium benzoate was used as a reference preservative at the rate of 1.5 g per 1000 g of ointment. The sodium benzoate and extract powder were triturated in a mortar with a pestle. Petroleum jelly was gradually added while slightly triturating until the mixture homogenized. Two ointments (in 3 and 10% petroleum jelly) were obtained according to the proportions (Table 2). The ointments were packaged in sealed jars and stored at room temperature away from the sun (Zdoryk et al., 2014).

**Table 2.** Composition of different ointments. CGPJ: *Combretum glutinosum* in petroleum jelly.

Composition	Placebo	Ointment	Ointment
	Petroleum jelly	CGPJ-3% (w/w)	CGPJ-10% (w/w)
Dry aqueous bark extract <i>C. glutinosum</i> (g)	0	1.5	5
Petroleum jelly (g)	49.925	48.425	44.925
Benzoate sodium (g)	0.075	0.075	0.075
Total (g)	50	50	50

**Table 3.** Scores of the evolution of experimental burns.

Score	Evaluation of the healing process
0	Healing is complete, tissue repair is complete
1	Tissue healing is almost completed
2	There are still vestiges of the crust, the lesion size decreases (skin reconstruction)
3	All dead tissue (scabs) are removed, ulceration, oozing
4	Necrosed skin is partially removed, ulceration, oozing
5	Necrosed skin completely covers the burned area

## Pharmacological tests

### Burn induction

Healing activity was evaluated in the experimental burn model (Gurung and Škalko-Basnet, 2009). Twenty-five rats were divided into 5 lots of 5 as follows:

- Lot 1: untreated rats
- Lot 2: control (petroleum jelly)
- Lot 3: sulfadiazine
- Lot 4: rats treated with ointment of 3% aqueous bark extract of *C. glutinosum* in petroleum jelly (CGPJ-3%).
- Lot 5: rats treated with ointment of 10% aqueous bark extract of *C. glutinosum* in petroleum jelly (CGPJ-10%).

Sulfadiazine is an antibacterial sulfonamide, used topically in preclinical and clinical studies to demonstrate the healing activity of a new product (Adhya et al., 2015; Nasiri et al., 2015).

The rats were then anesthetized with a 3% chloral solution by intra-peritoneal injection (1 mL/100 g). The dorsal flanks of the rats were shaved and cleaned. Experimental burns have been induced using a 3-cm diameter metal cylinder and heated for 5 min. The cylinder was applied for 20 s by slight pressing on the surface of the shaved skin of the rats to cause second degree burns (Hoşnüter et al., 2004).

### Evaluation of the healing activity of the aqueous bark extract of *C. glutinosum*

Healing activity was evaluated according to the Kamoshida's method, which assigns scores ranging from 1 to 5 depending on the importance of the burn (Table 3). Evaluation of the scores has been done daily during 28 days.

### Experimental protocol study of topical anti-inflammatory activity

Topical anti-inflammatory activity was evaluated in croton oil-induced ear edema in the experimental mice model (Tonelli et al., 1965; Tubaro et al., 1986).

The mice were divided into 3 lots of 3:

- Lot 1: control
- Lot 2: treated group with 10% *C. glutinosum* ointment
- Lot 3: treated group with 10% indomethacin ointment

In control group, the mice were treated locally with 10 µl of 1% croton oil in ethanolic solution applied to the right inner ear.

The ointments were applied on the left inner ear of mice. On the right inner ear, 10 µl of 1% croton oil in ethanolic solution and the ointments were also applied.

The treated animals were anesthetized with ethyl ether using a funnel 6 h after treatment. The ears were immediately cut along the cartilage and weighed immediately with a precision balance. The mice were then sacrificed.

Topical anti-inflammatory activity was evaluated using the following formulae:

$$\% \text{ INCREASE} = \frac{\text{RE Weight} - \text{LE Weight}}{\text{LE Weight}} \times 10$$

- RE: right ear,
- LE: left ear.

$$\% \text{ Inhibition} = \frac{\text{Mean (\% ) INC Control} - \text{Mean (\% ) INC treated Lot}}{\text{Mean (\% ) INC Control}} \times 100$$

INC: increase.


### Statistical analyses

The results were expressed as mean scores ± standard error of mean (SEM). Statistical significance was determined by analysis of the variance followed by the Bonferroni's test (graphPadPrism 5).

## RESULTS

### Phytochemical characterization

The results of phytochemical characterization of the



**Figure 1.** TLC of flavonoids, tannins and alkaloids. Tube characterization of sterols / triterpenes R: Rutin; AG: Gallic acid; E: Extract; C: Cinchonine.

aqueous bark extract of *C. glutinosum* revealed the presence of flavonoids, tannins and sterols/triterpenes. Alkaloids were not detected (Figure 1, Table 4).

## Pharmacological tests

### Healing activity

**Evolution of experimental second-degree burn scores in rats without treatment:** Seven days after the induction of experimental burn, the burned site was still covered with necrotic skin, corresponding to score 5. Three weeks after, in the absence of treatment, the burned site still showed an oozing ulcer (score 4).

Four weeks after, the experimental burn consisted of an open, oozing wound (score 2.75), corresponding to the absence of healing (Figure 2).

### Evolution of experimental second-degree burn scores in rats after daily application of petroleum jelly:

The daily application of petroleum jelly on a second-degree burn did not show significant difference in scores compared to the untreated group after 2 weeks. The burn score of 4 corresponded to an oozing ulceration. The score changes from 2.75 to 2.25, respectively, after 21 and 28 days (Figure 2).

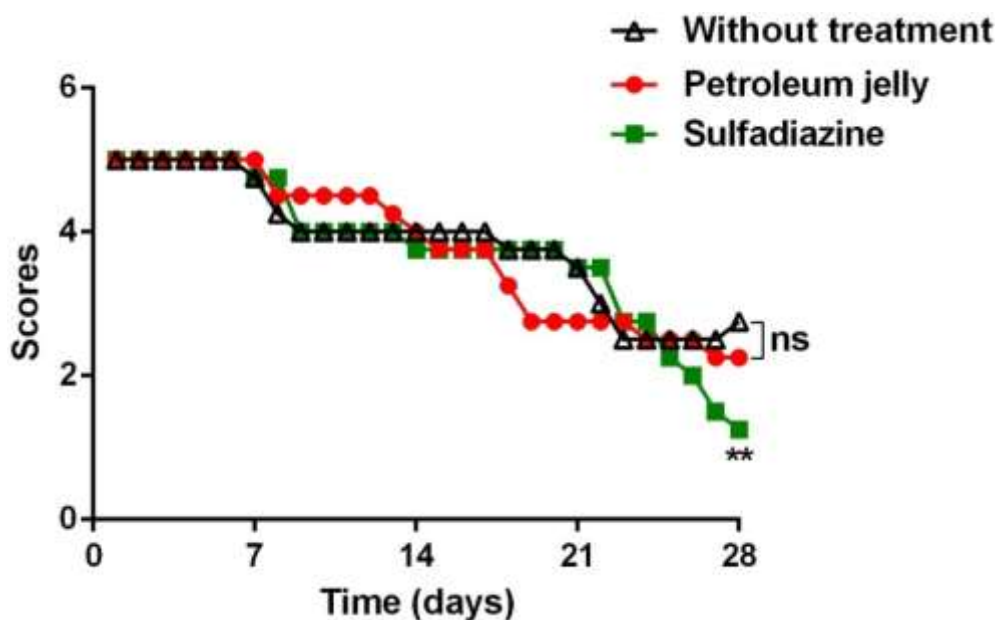
### Evolution of experimental second-degree burn scores in rats after daily application of Sulfadiazine:

The experimental burn score in the sulfadiazine group after 2 weeks of treatment was not significantly different from the untreated group or after petroleum jelly application. Three weeks after, the burn score was 3.5 corresponding to an oozing ulceration. Tissue repair was incomplete after 4 weeks, confirming a second-degree burn. Meanwhile, sulfadiazine, which was indicated in first-degree burn

**Table 4.** Phytochemical constituents of aqueous bark extract of *C. glutinosum*.

Group	Aqueous bark extract of <i>C. glutinosum</i>	Figure
Flavonoids	+	Figure 1A
Tannins	+	Figure 1B
Alkaloids	-	Figure 1C
Sterols/Triterpenes	+	Figure 1D / E

+ Presence; - Not detected

**Figure 2.** Effect of petroleum jelly and Sulfadiazine on a second degree burn in rats. \*\* =  $p < 0.01$  vs untreated group; ns = not significant.  $n = 4$ .

showed no healing effect (Figure 2).

**Evolution of experimental second-degree burn scores after treatment with an ointment of aqueous bark extract of *C. glutinosum* at 3 and 10% in petroleum jelly (CGPJ-3%, CGPJ-10%):** Daily application of CGPJ-3% was associated with burn healing. In fact, the score significantly decreased after 14 days of treatment (score 2.75). Tissue repair was complete after 28 days (score 0) (Figure 3). The cicatrization kinetic of *C. glutinosum* ointment is dependent on concentration. The daily application of CGPJ-10% shifts the healing curve to the left. Tissue repair was almost complete after 20 days (score 1) (Figure 4). Figure 5 shows the healing progress of the burns in rats treated with CGPJ-10% ointment.

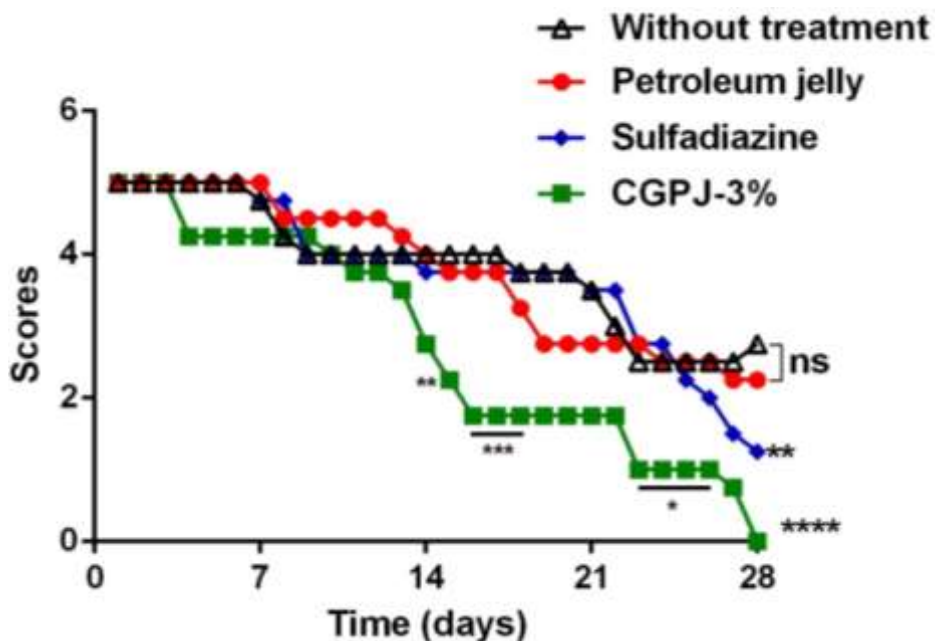
### Topical anti-inflammatory activity

Croton oil in ethanol induces inflammatory edema at percentage increase of  $70.59 \pm 5.18$ .

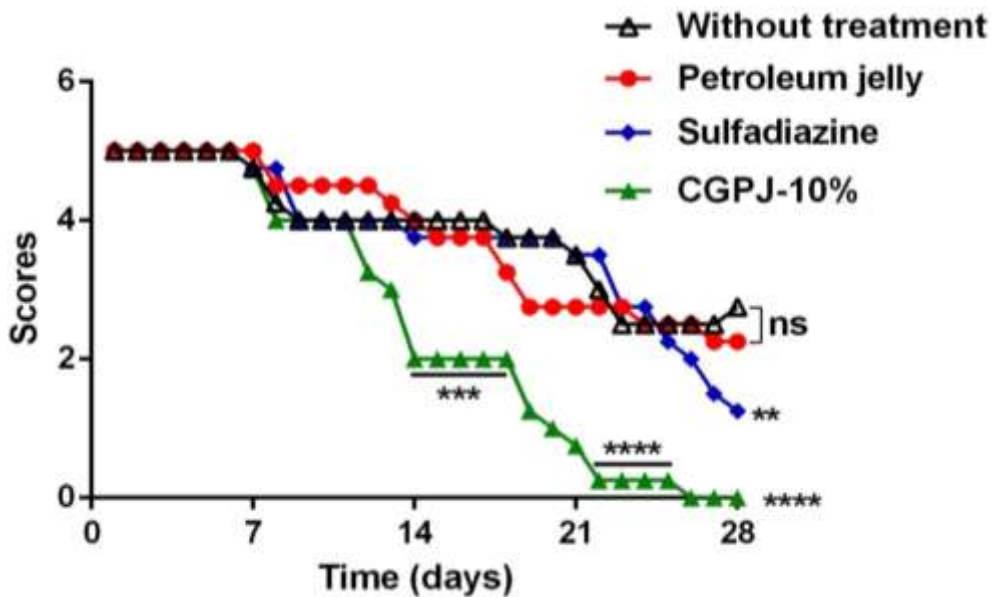
Application of the CGPJ-10% ointment significantly prevented ear edema in mice. The percentage increase in edema is  $42.78 \pm 4.94$  ( $p < 0.05$  versus control). The same profile is observed with the indomethacin ointment at 10%, used as a reference substance (Table 5).

### DISCUSSION

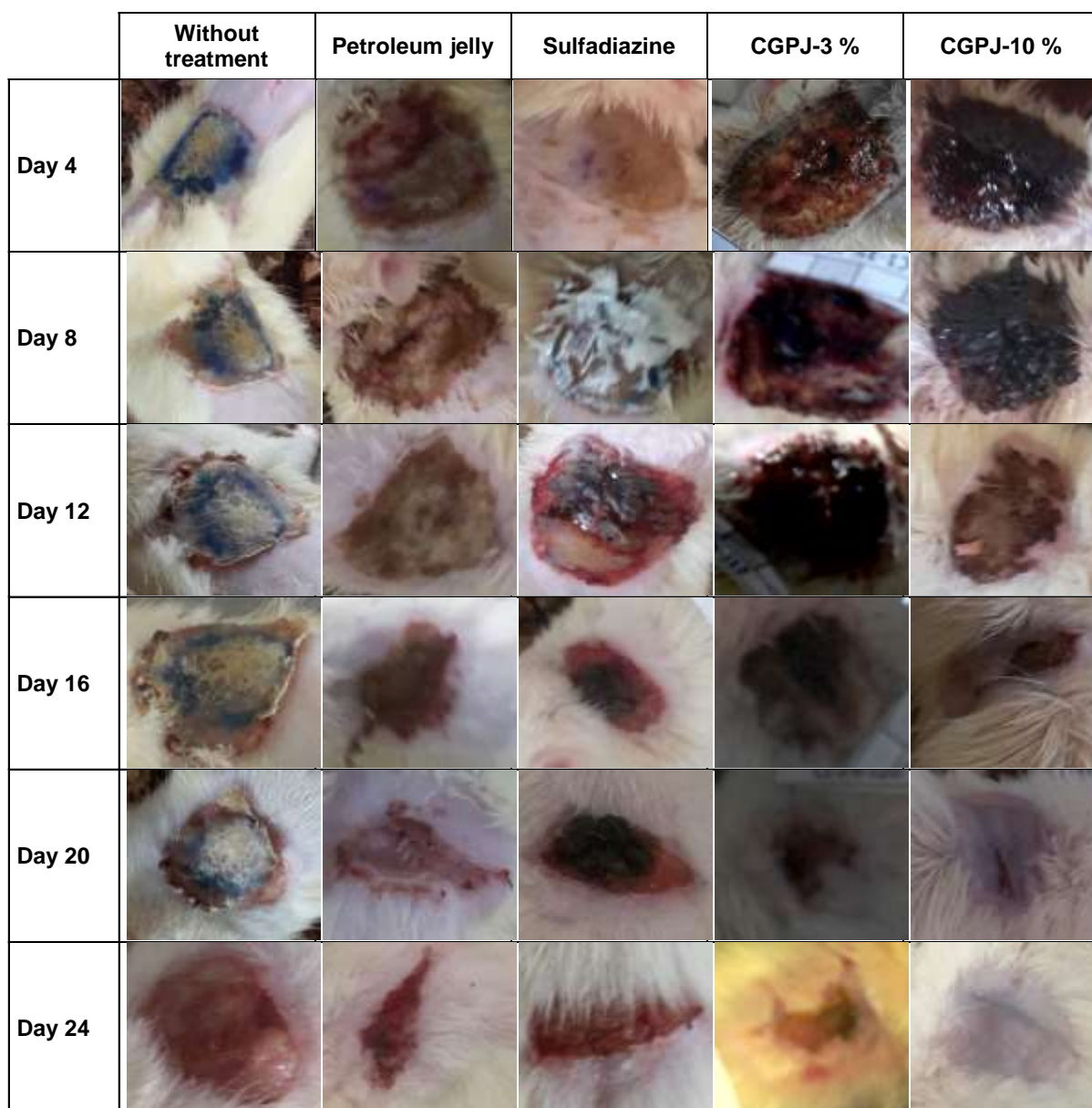
In African traditional medicine, the barks of *C. glutinosum* are used in the treatment of burns. The objective of this



**Figure 3.** Healing effect of aqueous bark extract of *C. glutinosum* (3%) in petrolatum jelly (CGPJ-3%).  
 \* = p<0.05 vs untreated group; \*\* = p<0.01 vs untreated group; \*\*\* = p<0.001 vs untreated group; \*\*\*\* = p <0.0001 vs untreated group; ns = not significant. n = 4.



**Figure 4.** Healing effect of an aqueous bark extract ointment of *C. glutinosum* 10 % in petrolatum jelly (CGPJ-10%).  
 \*\* = p <0.01 vs. untreated group; \*\*\* = p <0.001 vs. untreated group; \*\*\*\* = p <0.0001 vs. untreated group; ns = not significant. n =4.



**Figure 5.** Healing activity of the aqueous bark extract of *C. glutinosum*. The pictures show concentration-dependent healing of the aqueous bark extract of *C. glutinosum*, with full healing after 20 days. An oozing wound is observed in the group of untreated rats (Day 20).

study was to highlight the healing and anti-inflammatory activities of the trunk bark of *C. glutinosum*, on experimental second-degree burn model in Wistar rats and inflammatory croton oil edema in mice.

In the present study, the induction of second-degree burn in rats was not associated with complete healing

after 28 days of observation. Similar results were observed in the petroleum jelly treatment group, confirming that Carreiro and Fourtanier's (1983) observations according to which the vehicles usually employed to prepare ointments, such as petroleum jelly, did not have any specific effect in the healing process.

**Table 5.** Topical anti-inflammatory activity of aqueous bark extract ointment of *C. glutinosum* in petroleum jelly (CGPJ-10%).

Batches (n = 3)	Ear weight removed (g)		Increased edema (%)	Inhibition edema (%)
	Left (treated)	Straight (untreated)		
Control	0.041 ± 0.004	0.070 ± 0.01	70.59 ± 5.18	-
CGPJ -10%	0.038 ± 0.002	0.054 ± 0.002	42.78 ± 4.94 * ns	38.05 ± 10.94
Indomethacin 10%	0.039 ± 0.001	0.058 ± 0.01	47.05 ± 18.27 *	34.61 ± 23, 83

ns: not significant vs indomethacin; \* = p <0.05 vs control group.

The aqueous extract of *C. glutinosum* trunk bark has a concentration-dependent healing activity in experimental second-degree burn model in wistar rats. Previous studies had already described the healing activity of plants belonging to the Combretaceae family. In fact, fractions from hydroalcoholic extract of stem barks of *Terminalia arjuna* showed healing effects, resulting in increased tensile strength and re-epithelialization in respective experimental models of incision and excision wounds (Rane and Mengi, 2003; Chaudhari and Mengi, 2006). Also, the aqueous leaf extract of *Combretum micronatum* (Combretaceae), induces healing by stimulating the viability of human keratinocytes and dermal fibroblasts (Kisseih et al., 2015).

The healing effect of the bark of *C. glutinosum* may involve fibroblasts and proliferation stimulations during tissue reconstruction.

Phytochemically, the aqueous bark extract of *C. glutinosum* contains flavonoids, tannins and sterols/triterpenes but not alkaloids.

Previous studies revealed the presence of tannins, flavonoids and triterpenes in the barks of *C. glutinosum* (Sereme et al., 2011; Yahaya et al., 2012; Niass et al., 2015; Sall et al., 2017). The phytochemical results of this study corroborates previous studies which described the presence of sterols/triterpenes, tannins and flavonoids.

The healing activity of different phytochemical components has been shown in several studies. In fact, epicatechin gallate, a natural polyphenolic compound, significantly improves scar healing and quality in an incision wound model. These effects may be in part, caused by an acceleration of angiogenic response and upregulation of nitric oxide synthase and cyclooxygenase enzymes (Kapoor et al., 2004). The total tannins present in the aqueous powder extract of *Entada phaseoloides* showed a healing action in excision wound model of rat. This effect could not only be favored by improvement in fibroblasts proliferation and migration, but also by an antibacterial activity attributed to these tannins (Su et al., 2017).

A probable action of *C. glutinosum* bark on the proliferation and/or migration of fibroblasts could be related to the abundant presence of tannins in the aqueous extract.

A pentacyclic triterpenoid molecule isolated from leaves of *Lantana camara* (Verbanaceae), induces healing action in incision and excision wound models in experimental rats. This effect involves faster epithelialization and a significant increase in breaking strength (Pravez and Patel, 2014). Studies have attributed the healing activity to triterpenic structured molecules. In fact, Asian acids, madecoside and asiaticoside, extracted from *Centella asiatica*, promote healing in experimental model of excision and incision wounds in healthy and diabetic guinea pigs (Shukla et al., 1999; Lee et al., 2012). Deoxyelephantopine, a sesquiterpene lactone isolated from leaves of *Elephantopus scaber* (Asteraceae) causes healing in excision and incision wounds in rat models (Singh et al., 2005; Lee et al., 2012).

In addition, ointment of *C. glutinosum* aqueous bark extract in petroleum jelly (CGPJ-10%), which showed a better healing effect, prevented croton oil-induced ear edema in mice. Olajide et al. (2003) reported the anti-inflammatory activity of the methanolic leaf extract of *C. micranthum* (Combretaceae) in experimental carrageenan edema rat model. Recent studies have highlighted the anti-inflammatory activity of triterpene molecules (betulinic acid, cabralone), isolated from leaves of *C. glutinosum* (Sene et al., 2018).

The beneficial effect of the use of anti-inflammatories in wound and burn management has been widely demonstrated. Their use in the first phase of wound healing process promotes the reduction or control of inflammation. They also help accelerate healing and improve scar appearance (Rosique et al., 2015).

The healing activity of *C. glutinosum* trunk bark could probably be linked to the presence of tannins and sterols/triterpenes, through a mechanism which essentially involves stimulating fibroblasts proliferation, accelerating re-epithelialization and early control of inflammatory processes.



## Conclusion

The aqueous bark extract of *C. glutinosum* possesses both healing and topical anti-inflammatory activities which involve tannins and/or triterpenoids compounds, justifying the use of trunk bark of *C. glutinosum* in traditional medicine to treat wounds and burns.

## CONFLICT OF INTERESTS

The authors have not declared any conflict of interests.

## REFERENCES

- Adhya A, Bain J, Ray O, Hazra A, Adhicari S, Dutta G, Ray S, Majumdar BK (2015). Healing of burn wounds by topical treatment: a randomized controlled comparison between silver sulfadiazine and nano-crystalline silver. *Journal of Basic and Clinical Pharmacology* 6(1):29-34.
- Baba-Moussa F, Akpagana K, Bouchet P (1999). Antifungal activities of seven West African Combretaceae used in traditional medicine. *Journal of Ethnopharmacology* 66(3):335-338.
- Baldé E, Camara A, Traoré M, Mégalizzi V, Kahvecioglu Z, Colet J, Baldé A (2016). *Combretum glutinosum* has a dual hypoglycemic and cytotoxic activity. *Diabetes and Metabolism* 42(2):A42-A43.
- Bassène E (2012). Initiation à la recherche sur les substances naturelles. Extraction - Analyse - Essais biologiques. Presses Universitaires de Dakar. P 150.
- Carreiro S, Fourtanier A (1983). Sur la comparaison au cours du temps de l'efficacité de plusieurs traitements: application à la cicatrisation épidermique. *Cahiers de l'Analyse des Données* 8(1):101-112.
- Chang R-K, Raw A, Lionberger R, Yu L (2012). Generic development of topical dermatologic products: formulation development, process development, and testing of topical dermatologic products. *The AAPS Journal* 15(1):41-52.
- Chaudhari M, Mengi S (2006). Evaluation of phytoconstituents of *Terminalia arjuna* for wound healing activity in rats. *Phytotherapy Research* 20(9):799-805.
- Dione D (1996). Etude biosystématique et chimiotaxonomique de sept espèces affines du genre *Combretum* au Sénégal, Dakar: Doctorat de 3e Cycle - Université Cheikh Anta DIOP. Dissemond J, Goos M, Wagner SN (2002). The role of oxidative stress in the pathogenesis and therapy of chronic wounds. *Der Hautarzt; Zeitschrift für Dermatologie, Venerologie, und verwandte Gebiete* 53(11):718-723.
- Eming SA, Krieg T, Davidson JM (2007). Inflammation in wound repair: molecular and cellular mechanisms. *Journal of Investigative Dermatology* 127(3):514-525.
- Esimone CO, Nworu CS, Jackson CL (2008). Cutaneous wound healing activity of a herbal ointment containing the leaf extract of *Jatropha curcas* L. (Euphorbiaceae). *International Journal of Applied Research in Natural Products* 1(4):1-4.
- Gurung S, Škalko-Basnet N (2009). Wound healing properties of *Carica papaya* latex: *in vivo* evaluation in mice burn model. *Journal of Ethnopharmacology* 121(2):338-341.
- Hoşnüter M, Gürel A, Babuççu O, Armutcu F, Kargı E, Işıkdemir A (2004). The effect of CAPE on lipid peroxidation and nitric oxide levels in the plasma of rats following thermal injury. *Burns* 30(2):121-125.
- Kaboré IZ, Guissou IP, Sawadogo PL (2003). Evaluation de l'activité hépatoprotectrice des extraits aqueux de plantes médicinales face à une hépatotoxicité létale induite chez la souris. *Annales de l'Université de Ouagadougou* 1:15-40.
- Kapoor M, Howard R, Hall I, Appleton I (2004). Effects of epicatechin gallate on wound healing and scar formation in a full thickness incisional wound healing model in rats. *The American Journal of Pathology* 165(1):299-307.
- Kerharo J, Adam JG (1974). La pharmacopée sénégalaise traditionnelle: plantes médicinales et toxiques. Paris: Éditions Vigot frères. 1011p.
- Kisseih E, Lechtenberg M, Petereit F, Sendker J, Zacharski D, Brandt S, Hensel A (2015). Phytochemical characterization and *in vitro* wound healing activity of leaf extracts from *Combretum mucronatum* Schum. & Thonn: Oligomeric procyanidins as strong inducers of cellular differentiation. *Journal of Ethnopharmacology* 174:628-636.
- Kumar B, Vijayakumar M, Govindarajan R, Pushpangadan P (2007). Ethnopharmacological approaches to wound healing-exploring medicinal plants of India. *Journal of Ethnopharmacology* 114(2):103-113.
- Lee JH, Kim HL, Lee MH, You KE, Kwon BJ, Seo HJ, Park JC (2012). Asiaticoside enhances normal human skin cell migration, attachment and growth in *in vitro* wound healing model. *Phytomedicine* 19(13):1223-1227.
- Mayba JN, Goderham MJ (2017). Guide to topical vehicle formulations. *Journal of Cutaneous Medicine and Surgery* 22(2):207-212.
- Mesfin F, Demissew S, Teklehaymanot T (2009). An ethnobotanical study of medicinal plants in Wonago Woreda, SNNPR, Ethiopia. *Journal of Ethnobiology and Ethnomedicine* 5(1):28.
- Muthu C, Ayyanar M, Raja N, Ignacimuthu S (2006). Medicinal plants used by traditional healers in Kancheepuram District of Tamil Nadu, India. *Journal of Ethnobiology and Ethnomedicine* 2(1):43.
- Nasiri E, Hosseinimehr SJ, Azadbakht M, Akbar J, Enayati-Fard R, Azizi S (2015). The effect of *Terminalia chebula* extract vs. Silver sulfadiazine on burn wounds in rat. *Journal of Complementary and Integrative Medicine* 12(2): 127-135.
- Niass O, Sarr SO, Diop A, Diop YM (2015). Etude *in vitro* de l'activité antibactérienne de quelques plantes utilisées en médecine traditionnelle locale au Saloum (Sénégal). *La Science en Liberté* 7(150801):1-10.
- Olajide OA, Makeinde JM, Okpako DT (2003). Evaluation of the anti-inflammatory property of the extract of *Combretum micranthum* G. Don (Combretaceae). *Inflammopharmacology* 11(3):293-298.
- Quattara Y, Sanon S, Traoré Y, Mahiou V, Azas N, Sawadogo L (2006). Antimalarial activity of *Swartzia madagascariensis* desv. (Leguminosae), *Combretum glutinosum* Guill. & Perr. (Combretaceae) and *Tinospora bakis* Miers. (Menispermaceae), Burkina Faso medicinal plants. *African Journal of Traditional, Complementary and Alternative Medicines* 3(1):75-81.
- Pravez M, Patel AK (2014). Wound healing activity of ursolic acid stearoyl glucoside (UASG) isolated from *Latana camara*. *International Journal of Pharmaceutical Sciences and Research* 5(10):4439-4444.
- Rane MM, Mengi SA (2003). Comparative effect of oral administration and topical application of alcoholic extract of *Terminalia arjuna* bark on incision and excision wounds in rats. *Fitoterapia* 74(6):553-558.
- Rosique RG, Rosique MJ, Junior F, Jayme A (2015). Curbing inflammation in skin wound healing: a review. *International Journal of Inflammation* pp. 1-9. <https://www.hindawi.com/journals/ijji/2015/316235/>
- Sadaf F, Saleem R, Ahmed M, Ahmad SI (2006). Healing potential of cream containing extract of *Sphaeranthus indicus* on dermal wounds in Guinea pigs. *Journal of Ethnopharmacology* 107(2):161-163.
- Sall C, Ndoye SF, Dioum MD, Seck I, Gueye RS, Faye B, Thiam CO, Seck M, Gueye PM, Fall D, Fall M, Dieye TN (2017). Phytochemical Screening, Evaluation of Antioxidant and Anti-sickling Activities of Two Polar Extracts of *Combretum glutinosum* Leaves. *Perr. ex DC. British Journal of Applied Science and Technology* 19(3):1-11.
- Sene M, Ndiaye D, Gassama A, Barboza FS, Mbaye MD, Sy GY (2018). Analgesic and Anti-inflammatory activities of triterpenoid molecules isolated from the leaves of *Combretum glutinosum* Perr. Ex DC

- (Combretaceae). Journal of Advances in Medical and Pharmaceutical Sciences 19(4):1-8.
- Sereme A, Milogo-Rasolodimby J, Guinko S, Nacro M (2011). Propriétés thérapeutiques des plantes à tanins du Burkina Faso. Pharmacopée et Médecine Traditionnelle Africaines 15:41-49.
- Shukla A, Rasik AM, Jain GK, Shankar R, Kulshrestha DK, Dhawan BN (1999). In vitro and in vivo wound healing activity of asiaticoside isolated from *Centella asiatica*. Journal of Ethnopharmacology 65(1):1-11.
- Singh SDJ, Krishna V, Mankani KL, Manjunatha BK, Vidya SM, Manohara YN (2005). Wound healing activity of the leaf extracts and deoxyelephantopin isolated from *Elephantopus scaber* Linn. Indian Journal of Pharmacology 37(4):238-242.
- Su X, Liu X, Wang S, Li B, Pan T, Liu D, Li K (2017). Wound-healing promoting effect of total tannins from *Entada phaseoloides* (L.) Merr. in rats. Burns 43(4):830-838.
- Tonelli G, Thibault L, Ringler I (1965). A Bio-assay for the Concomitant Assessment of the Antiphlogistic and Thymolytic Activities of Topically Applied Corticoids. Endocrinology 77(4):625-634.
- Tubaro A, Dri P, Delbello G, Zilli C, Loggia RD (1986). The croton oil ear test revisited. Inflammation Research 17(3):347-349.
- Yahaya O, Yabefa JA, Usman B (2012). Phytochemical screening and antibacterial activity of *Combretum glutinosum* extract against some human pathogens. British Journal of Pharmacology and Toxicology 3(5):233-236.
- Zdoryk OA, Khokhlova KO, Georgyants VA, Vyshnevskaya LI (2014). Investigation of physical and chemical stability of ointment with herbals. The International Journal of Pharmaceutical Compounding 18(3):248-252.